

Functional repair of the great saphenous vein by external valvuloplasty reduces the vein's diameter: 6-month results of a multicentre study

Journal of International Medical Research

49(5) 1–9

© The Author(s) 2021


Article reuse guidelines:

sagepub.com/journals-permissions

DOI: 10.1177/03000605211014364

journals.sagepub.com/home/imr



Dominic Mühlberger^{1,2} , Erich Brenner³,
Norbert Frings⁴, Bruno Geier⁵,
Achim Mumme^{1,2}, Stefanie Reich-Schupke²,
Horst-Peter Steffen⁶, Dietmar Stenger⁷,
Markus Stücker^{2,8} and Thomas Hummel^{1,2}

Abstract

Objectives: External valvuloplasty (eVP) is a reconstructive surgical method to repair the function of the terminal and preterminal valves. We evaluated the 6-month outcomes of eVP regarding the diameter of the great saphenous vein (GSV).

Methods: Patients from five vein centres were included in this observational study. Follow-up involved detailed duplex sonography of the GSV. The venous clinical severity score (VCSS) and the C class of the clinical, aetiologic, anatomic and pathophysiologic (CEAP) classification were recorded.

Results: We enrolled 210 patients, with a follow-up rate of 58%; eVP was sufficient in 95.24% of the patients. The GSV diameters decreased significantly from 4.4 mm (standard deviation

¹Department of Vascular Surgery, St. Josef Hospital Bochum, Katholisches Klinikum Bochum Department of the Ruhr University Bochum, Bochum, Germany

²Vein Centre of the Departments of Dermatology and Vascular Surgery, Katholisches Klinikum Bochum, Bochum, Germany

³Institute for Clinical and Functional Anatomy, Department of Anatomy, Histology and Embryology, Medical University of Innsbruck, Austria

⁴Vein Centre Capio Bad Bertrich GmbH, Bad Bertrich, Germany

⁵Department of Vascular Surgery, Krankenhaus Bethanien Moers, Germany

⁶Vein Centre Capio Clinic im Park, Hilden, Germany

⁷Gemeinschaftspraxis Saarlouis, Saarlouis, Germany

⁸Department of Dermatology, St. Josef Hospital Bochum, Katholisches Klinikum Bochum, Department of the Ruhr University Bochum, Bochum, Germany

Corresponding author:

Dominic Mühlberger, Department of Vascular Surgery, St. Josef Hospital Bochum, Katholisches Klinikum Bochum, Clinic of the Ruhr University Bochum, Gudrunstr. 56, Bochum 44791, Germany.

Email: dominic.muehlberger@gmail.com



(SD): 1.39) to 3.9 (SD: 1.12), 4 cm distal to the saphenofemoral junction (SFJ); from 3.7 mm (SD: 1.10) to 3.5 mm (SD: 1.02) at the mid-thigh; from 3.6 mm (SD: 1.14) to 3.3 mm (SD: 0.94) at the knee and from 3.1 mm (SD: 0.99) to 2.9 mm (SD: 0.78) at the mid-calf. VCSS decreased significantly from 4.76 (SD: 2.13) preoperatively to 1.77 (SD: 1.57) 6 months postoperatively.

Conclusions: GSV function can be restored by eVP; diameters over the total length of the GSV decreased significantly.

Keywords

Great saphenous vein, venous reflux, varicose vein, external valvuloplasty, saphenofemoral junction, reconstruction

Date received: 23 December 2020; accepted: 6 April 2021

Introduction

Chronic venous disease is a frequent problem with high socioeconomic impact in Western countries.¹ Varicose veins mainly develop because of reflux in superficial or deep veins,² although reflux is limited to the superficial system in one-third of the patients.³ Concerning the superficial venous system, reflux mostly occurs in the great saphenous vein and increases with age.⁴ Furthermore, reflux is associated with the vein's diameter.^{5,6} The great saphenous vein diameters at the saphenofemoral junction and the thigh could be relevant, as they can correlate with the venous clinical severity score (VCSS).⁷ In this context, a value of 5 mm in the lower thigh is a reported cut-off.⁵ Moreover, there is an association between a great saphenous vein diameter of 5 mm and a competent terminal valve.⁸ Generally, there is a positive correlation between truncal diameters and higher clinical ("C") classes of the clinical, aetiologic, anatomic and pathophysiologic (CEAP) classification^{6,9} and the presence of venous symptoms.⁶ Therefore, eliminating reflux is the principle of all treatment strategies. Currently, surgical and endovenous methods are widely

used.¹⁰ The great saphenous vein is removed during high ligation and stripping, whereas the vein is destroyed or occluded during endovenous thermal or non-thermal procedures.¹⁰ Only a few vein-sparing procedures attempt to restore the vein's function, which is generally a high-level goal in many surgical treatments. As treatment methods, ambulatory selective varices ablation under local anaesthesia (ASVAL), Cure Conservatrice et Hémodynamique de l'Insuffisance Veineuse en Ambulatoire strategy (CHIVA), and external valvuloplasty (eVP) have been described.^{11–13} eVP is a reconstructive surgical method aimed at repairing the function of the terminal and preterminal valve.¹⁴ In our department, we achieve this by implanting a u-shaped patch at the saphenofemoral junction,¹⁵ although other devices can be used.^{12,16,17} This patch covers the great saphenous vein to reduce the vein's diameter, which permits the valve leaflets to open and close sufficiently again.¹⁴ However, this procedure is limited to approximately 15% of all varicose veins patients.¹⁵ Although excellent long-term results with a recurrence rate of 4.6% after 68.5 months and improved venous hemodynamics have been described after

eVP,^{17–19} there is a lack of data because most studies are single-centre.²⁰ Therefore, we performed this prospective multicentre study involving five high-volume vein centres in Germany. The short-term (6 weeks) results of the safety and functionality of eVP were published recently.¹⁴ The aim of the current study was to elucidate the outcomes 6 months after eVP, with specific evaluation of the great saphenous vein diameters at several anatomical levels.

Material and methods

eVP

eVP was performed as previously described^{14,21} according to a standardised protocol and under a preoperative single dose of antibiotic. Specifically, the great saphenous vein was exposed via a standard inguinal approach, and all side branches were ligated. After identifying the saphenofemoral junction and the common femoral vein, we modified a preformed 4- × 2-cm non-absorbable polyurethane patch with a u-shaped gap (VenoPatch®; B. Braun Melsungen AG, Melsungen, Germany) around the great saphenous vein (Figure 1). The patch was fixed like a cuff with 4 to 5 sutures to reduce the diameter of the vein to ≤ 5 mm to repair the terminal and preterminal valves. The restored valve's function after eVP was controlled intraoperatively by an indicator vein, as previously described.^{14,15} Afterwards, the two flaps of the patch were fixed on the common femoral vein by two additional sutures. Finally, multiple phlebectomies of side branches were performed. We added elastic compression bandages for 1 day postoperatively and recommended the use of compression hosiery with an ankle pressure of 18 to 23 mmHg (German class 2) for 6 weeks.

Reflux of more than 0.5 s was considered pathological.²² Patients with a great saphenous vein diameter at the level of the

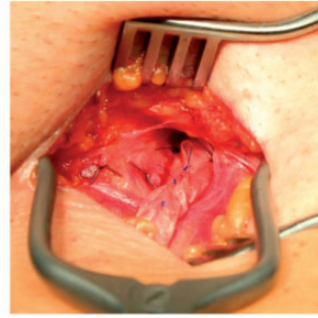


Figure 1. Scheme of external valvuloplasty.

terminal valve between 5 and 12 mm and duplex-sonographically visible, mobile valvular leaflets of the terminal and preterminal valves were eligible for eVP.

Follow up

Follow-up examination involved detecting reflux in the great saphenous vein, especially at the saphenofemoral junction, to assess the functional results of eVP. eVP was considered sufficient if there was no reflux or occlusion of the GSV at the saphenofemoral junction. Additionally, the great saphenous diameters were measured at the following previously defined points: 4 cm distal to the saphenofemoral junction, at the mid-thigh, at the knee and at the mid-calf. Reflux was measured according to Hach stage (Hach I: reflux at the saphenofemoral junction and insufficiency of the anterior accessory great saphenous vein; Hach II: reflux to the knee; Hach III: reflux to the calf and Hach IV: reflux in the entire vein, from the saphenofemoral junction to the ankle.²³ The VCSS and the C class of the CEAP classification were also recorded.^{24,25}

Ethics

The study was approved by the Ethics Committee (Registry Number 5024 -14 in 2014) of the medical faculty of the Ruhr

Table 1. Assessment of overall outcomes 6 months after external valvuloplasty (eVP) (eVP and the great saphenous vein (GSV) were assessed by duplex sonography).

	eVP sufficient, n (%)	GSV suitable as a potential bypass graft?, n (%)	Are you satisfied with the therapy?, n (%)	Would you undergo eVP again?, n (%)
Yes	200 (95.24%)	191 (90.95)	186 (88.57)	195 (92.86)
No	9 (4.29%)	14 (6.67)	19 (9.05)	9 (4.29)
Missing data	1 (0.48%)	5 (2.38)	5 (2.38)	6 (2.86)

Data are n (%).

University of Bochum. Patients provided written informed consent.

Statistical analysis

Statistical analyses were performed using PSPP (GNU PSPP Statistical Analysis Software, Release 1.2.0-g07fb-4db; Free Software Foundation, Boston, MA, USA) and Microsoft Excel (Microsoft, Redmond, WA, USA) (paired Student's t-test, χ^2 test). We performed an intention-to-treat analysis, and $p < 0.05$ was considered significant.

Results

Patients

Initially, we included 359 symptomatic patients with great saphenous vein reflux in this observational study between 2015 and 2019; 210 patients were available for the 6-month follow-up by an intention-to-treat analysis, representing a follow-up rate of 58%.

General outcomes

The patients' mean age was 48.1 years (standard deviation (SD): 10.8). The patients had a mean height of 1.68 m (SD: 0.08) and a mean weight of 78.03 kg (SD: 16.07). The mean body mass index was 27.58 (SD: 5.48). Even though 95.24% (200/210) of our patients underwent duplex sonography, which indicated

sufficient eVP; we identified nine patients (4.29%) with treatment failure after 6 months. We detected one superficial vein thrombosis of the great saphenous vein, which was treated with compression therapy and anticoagulation with fondaparinux at 2.5 mg per day for 45 days. Overall, 88.57% (186/210) of the participants were satisfied with the outcome, and 92.86% (195/200) indicated they would undergo eVP again. Furthermore, the great saphenous vein was considered suitable as a bypass graft in 90.95% of the patients (Table 1).

Preoperatively, there were 111 (52.8%) patients with stage C2 disease and 50 (23.8%) patients with stage C3 disease according to the CEAP classification. After eVP, there were 137 (65.2%) patients with spider veins or telangiectasia, and 62 (29.52%) patients received additional sclerotherapy within the 6-month follow-up. No patients had stage C5 or C6 disease (Table 2). The mean total VCSS was 4.76 (SD: 2.13) preoperatively, 2.58 (SD: 1.78) 6 weeks after surgery and 1.77 (SD: 1.57) 6 months postoperatively.

Reflux

Initially, most patients (141/210, 67.14%) had Hach stage I with reflux in the saphenofemoral junction continuing into the anterior accessory great saphenous vein. Three patients were classified as Hach 0,

Table 2. Clinical class of the CEAP classification before and 6 months after external valvuloplasty (eVP).

C class	Before eVP (n)	6 months after eVP (n)
C 0	0	8
C 1	9	137
C 2	111	25
C 3	50	0
C 4	3	1
Missing data	37	39

CEAP, clinical, aetiologic, anatomic and pathophysiologic grading system.

Table 3. Extent of reflux in the great saphenous vein before and 6 months after external valvuloplasty (eVP).

Reflux	Before eVP (n)	6 months after eVP (n)
Hach 0 (no reflux at the terminal valve)	3	139
Hach I (reflux at the SFJ)	141	4
Hach II (reflux to the knee)	8	2
Hach III (reflux to the calf)	9	3
Hach IV (reflux to the ankle)	5	0
Missing data	44	62

Hach 0 is defined preoperatively as a competent terminal valve, but an insufficient preterminal valve. SFJ, saphenofemoral junction.

which represents a competent terminal valve preoperatively, but an incompetent preterminal valve, according to Stücker class 2.²⁶ Reflux changed after eVP treatment (Table 3).

Diameter of the great saphenous vein

The mean diameter of the great saphenous vein at the saphenofemoral junction at the level of the terminal valve was 7.3 mm (SD: 1.91) before treatment. The mean diameter of the great saphenous vein 4 cm distal to the saphenofemoral junction was 4.4 mm

(SD: 1.39) preoperatively, 3.8 mm (SD: 0.97) 6 weeks postoperatively and 3.9 mm (SD: 1.12) 6 months postoperatively. The mean diameter of the great saphenous vein at the mid-thigh was 3.7 mm (SD: 1.10) preoperatively, 3.4 mm (SD: 1.00) 6 weeks postoperatively and 3.5 mm (SD: 1.02) 6 months postoperatively. The mean diameter of the great saphenous vein at the knee was 3.6 mm (SD: 1.14) before eVP, 3.4 mm (SD: 0.97) 6 weeks after eVP and 3.3 mm (SD: 0.94) 6 months after eVP. Finally, the mean diameter of the great saphenous vein at the mid-calf was 3.1 mm (SD: 0.99) preoperatively, 2.9 mm (SD: 0.84) 6 weeks postoperatively and 2.9 mm (SD: 0.78) 6 months postoperatively. The values before and after eVP were statistically significant ($p < 0.05$) whereas there was no significant difference between 6 weeks and 6 months (Table 4).

Discussion

Our data demonstrated that the diameters of the great saphenous vein decreased significantly 6 months after eVP. Joh et al. showed that the diameters of the vein at the saphenofemoral junction and at the knee were significantly decreased 10 years after eVP. However, the authors could not demonstrate a reduction in the overall length of the vein. Notably, the authors did not precisely define the measurement points, and they reinvestigated only 32 limbs.¹⁷ Furthermore, 61.3% of the patients had reflux in the proximal great saphenous vein, which could have influenced the results.¹⁷ Sarac et al.¹⁸ also found a decreased diameter of the great saphenous vein at the saphenofemoral junction. The authors described a significant reduction from 5.6 mm preoperatively to 3.1 mm postoperatively on the first postoperative day. Seven years after the treatment, the authors reported a mean diameter at the saphenofemoral junction of 4.5 mm, but

Table 4. Diameters of the great saphenous vein (GSV) before and six months after external valvuloplasty (eVP) (SFJ: saphenofemoral junction).

Diameter of the GSV	preoperative / 6 months	p	6 weeks / 6 months	p
4 cm distally to the SFJ	4.4 / 3.9	0.000	3.8 / 3.9	>0.05
mid-thigh	3.7 / 3.5	0.026	3.4 / 3.5	>0.05
knee	3.6 / 3.3	0.007	3.4 / 3.3	>0.05
mid-calf	3.1 / 2.9	0.004	2.9 / 2.9	>0.05

did not state the significance level.¹⁸ Geier et al.¹⁵ measured the diameter of the great saphenous vein in their study with a 5-year follow-up. The authors reported a significant reduction in the great saphenous vein diameter from 7.1 mm to 4.3 mm at the great saphenous junction and from 6.5 mm to 4.5 mm 3 cm distal to the junction.¹⁵ However, the surgical techniques differed in previous studies. Sarac et al. used a polytetrafluoroethylene (PTFE)-covered nitinol frame, and Lane et al.^{18,19} used a specially designed “exostent” device. Only the methods of Joh et al. and Geier et al. were similar to our technique, although Geier et al.^{15,17} used a piece of Dacron (Invista Inc., Wilmington, DE, USA) as a wrap.

In our previous study, we demonstrated decreased great saphenous vein diameters 6 weeks after eVP.¹⁴ Patients were encouraged to wear compression stockings for 6 weeks postoperatively, which could have influenced the 6-week follow-up results.¹⁴ In the current analysis, we demonstrated a significant decrease in the diameter of the great saphenous vein over its entire length 6 months after eVP. This indicates restored vein function because there were no statistically significant differences between the 6-week and 6-month results. Nevertheless, it remains unclear which factors are responsible for these findings. According to the ascending theory,¹¹ decreased venous volume in the leg following multiple phlebectomies can also decrease truncal diameter.^{27,28} Because all of our patients underwent multiple additional

phlebectomies, the interpretation of these data is limited. Furthermore, 29.52% of our patients underwent additional sclerotherapy of spider veins or reticular veins during follow-up. It seems unlikely that the occlusion of spider veins affected the venous reservoir and subsequently the venous diameter of the great saphenous vein; however, this could have influenced our results.

The descending theory focuses on saphenous vein reflux with centrifugal progression of the disease,²⁹ which is the crucial point of eVP. Because reflux can develop in a multicentric way,²⁹ both factors (eVP and multiple phlebectomies) may have influenced our data concerning the reduction in the vein’s diameters. Only long-term follow-up studies will address this issue.

eVP appears to be an effective treatment considering that 95.24% of our patients showed no reflux at the saphenofemoral junction 6 months postoperatively. Generally, reflux improved significantly, and the results are similar to findings in our previous study.¹⁴ Surprisingly, three patients had great saphenous vein reflux from the saphenofemoral junction to the calf (Hach III stage) in this analysis. Unfortunately, eVP was insufficient treatment in nine patients; however, no further interventions to the great saphenous vein have been necessary to date. Nevertheless, it is feasible that these patients will require earlier additional treatment to address recurrent varicose veins, as reflux at the

saphenofemoral junction is one of the most common causes of recurrent varicose veins.³⁰ However, the vein was preserved as a potential bypass graft in 9 of 10 cases. Overall, 88.57% of the patients were satisfied with the treatment, and 92.86% stated they would undergo eVP again, similar to the 6-week results in our previous study.¹⁴ The most frequent reasons for dissatisfaction were new or remaining varicosities (n=4), restless legs or paraesthesia (n=2), hyperpigmentation (n=2) or non-improvement of symptoms (n=2). Even though C class grade decreased significantly, 65.2% (137/210) of our patients had spider veins or telangiectasia, and nearly one third (29.52%) underwent additional treatment with sclerotherapy.

Limitations

This study has certain limitations. First, we had a high lost-to-follow-up rate, and we reinvestigated only 210 of 359 patients, which represents a follow-up rate of only 58%. We attempted to motivate patients to participate in the follow-up examination using multiple phone calls. However, as re-examinations mainly took place in the afternoon, the majority of patients did not respond for occupational reasons. Nevertheless, the population's general data were similar to the preoperative and 6-week data, indicating a comparable study population.¹⁴ eVP is limited to approximately 15% of all patients¹⁵ and patients with reflux at the saphenofemoral junction and continuing reflux in the accessory anterior saphenous vein benefit the most from eVP.¹⁴ Therefore, our data represent a highly selective group of patients, which is a further limitation. Moreover, we had a high number of missing data for the reflux measurements, which is another strong limitation. Overall, this was an intention-to-treat-analysis, and we evaluated 210 patients from five vein centres, which is a

strength of this study. In contrast to other studies,^{15,17,18} we measured the diameter of the great saphenous vein over its entire length at predefined measurement points, which represents another advantage.

Conclusion

eVP appears to be a sufficient treatment strategy to reduce venous reflux at the saphenofemoral junction; 95.24% of our patients achieved sufficient venous reconstruction of the function of the terminal and preterminal valves. Furthermore, the C class of the CEAP classification and VCSS scores improved significantly after eVP. The diameters of the entire great saphenous vein decreased significantly 6 months after eVP.

Acknowledgment

This manuscript was created under a rehabilitation scholarship from the Ruhr University Bochum (supported by Bauerfeind AG).

Declaration of conflicting interest

Markus Stücker received consulting fees from Bauerfeind AG.

Funding

This research received no specific grant from any funding agency in the public, commercial, or not-for-profit sectors.

Author contributions

TH, AM and MS searched the literature and conceived the study. BG, SRS, NF, DS, HS and DM were involved in protocol development and patient recruitment. TH was responsible for obtaining ethical approval. EB and DM conducted the statistical analyses. DM and TH wrote the first draft of the manuscript. All authors analysed and interpreted the data, critically revised the first draft for intellectual content and approved the final version of the manuscript.

ORCID iD

Dominic Mühlberger  <https://orcid.org/0000-0001-9636-5108>

References

1. Davies AH. The seriousness of chronic venous disease: a review of real-world evidence. *Adv Ther* 2019; 36: 5–12. DOI: 10.1007/s12325-019-0881-7.
2. Wittens C, Davies AH, Bækgaard N, et al. Editor's Choice - Management of chronic venous disease: clinical practice guidelines of the European Society for Vascular Surgery (ESVS). *Eur J Vasc Endovasc Surg* 2015; 49: 678–737. DOI: 10.1016/j.ejvs.2015.02.007.
3. Ruckley CV, Evans CJ, Allan PL, et al. Chronic venous insufficiency: clinical and duplex correlations. The Edinburgh Vein Study of venous disorders in the general population. *J Vasc Surg* 2002; 36: 520–525. DOI: 10.1067/mva.2002.126547.
4. Maurins U, Hoffmann BH, Lösch C, et al. Distribution and prevalence of reflux in the superficial and deep venous system in the general population—results from the Bonn Vein Study, Germany. *J Vasc Surg* 2008; 48: 680–687. DOI: 10.1016/j.jvs.2008.04.029.
5. Kim MJ, Park PJ, Koo BH, et al. Association between venous reflux and diameter of great saphenous vein in lower thigh. *J Vasc Surg Venous Lymphat Disord* 2020; 8: 100–105. DOI: 10.1016/j.jvsv.2019.04.016.
6. Hamel-Desnos CM, De Maeseneer M, Josnin M, et al. Great saphenous vein diameters in phlebological practice in France: a report of the DIAGRAVES Study by the French Society of Phlebology. *Eur J Vasc Endovasc Surg* 2019; 58: 96–103. DOI: 10.1016/j.ejvs.2018.09.011.
7. Mendoza E, Amsler F and Kalodiki E. Correlation between GSV diameter and varicose clinics. *Phlebologie* 2016; 45: 29–35. DOI: <http://dx.doi.org/10.12687/phleb2291-1-2016>.
8. Cappelli M, Molino Lova R, Ermini S, et al. Hemodynamics of the sapheno-femoral junction. Patterns of reflux and their clinical implications. *Int Angiol* 2004; 23: 25–28.
9. Tan MKH, Sutanto SA, Onida S, et al. The relationship between vein diameters, clinical severity, and quality of life: a systematic review. *Eur J Vasc Endovasc Surg* 2019; 57: 851–857. DOI: 10.1016/j.ejvs.2019.01.024.
10. Mitschang C, Mühlberger D and Goerge T. [Pros and cons of classic crosssectomy with stripping compared to endoluminal treatment: competition or team play?]. *Hautarzt* 2020; 71: 6–11. DOI: 10.1007/s00105-019-04515-z.
11. Onida S and Davies AH. CHIVA, ASVAL and related techniques—concepts and evidence. *Phlebology* 2015; 30: 42–45. DOI: 10.1177/0268355515591439.
12. Lane RJ, Cuzzilla ML and Coroneos JC. The treatment of varicose veins with external stenting to the saphenofemoral junction. *Vasc Endovascular Surg* 2002; 36: 179–192. DOI: 10.1177/153857440203600304.
13. Faccini FP, Ermini S and Franceschi C. CHIVA to treat saphenous vein insufficiency in chronic venous disease: characteristics and results. *J Vasc Bras* 2019; 18: e20180099. DOI: 10.1590/1677-5449.009918.
14. Mühlberger D, Brenner E, Brockhoff H, et al. External valvuloplasty of the saphenofemoral junction in insufficient great saphenous veins - six weeks results of a prospective multicentre trial. *Vasa* 2020; 49: 411–417. DOI: 10.1024/0301-1526/a000874.
15. Geier B, Voigt I, Marpe B, et al. External valvuloplasty in the treatment of greater saphenous vein insufficiency: a five year follow up. *Phlebology* 2003; 18: 137–142.
16. Camilli D, Platone A, Ruggeri M, et al. Use of a novel device in reconstructive venous surgery: preliminary results. *Int J Angiol* 2020; 29: 245–249. DOI: 10.1055/s-0040-1715132.
17. Joh JH, Lee KB, Yun WS, et al. External banding valvuloplasty for incompetence of the great saphenous vein: 10-year results. *Int J Angiol* 2009; 18: 25–28. DOI: 10.1055/s-0031-1278318.
18. Sarac A, Jahollari A, Talay S, et al. Long-term results of external valvuloplasty in adult patients with isolated great saphenous vein insufficiency. *Clin Interv Aging* 2014; 9: 575–579. DOI: 10.2147/cia.S60555.

19. Lane RJ, Cuzzilla ML, Coroneos JC, et al. Recurrence rates following external valvular stenting of the saphenofemoral junction: a comparison with simultaneous contralateral stripping of the great saphenous vein. *Eur J Vasc Endovasc Surg* 2007; 34: 595–603; discussion 604. DOI: 10.1016/j.ejvs.2007.06.021.
20. Mumme A, Stücker M and Hummel T. Die extraluminale Valvuloplastie der Vena saphena magna. *Gefäßchirurgie* 2014; 637–642.
21. Mühlberger D, Burkert B, Mumme A, et al. External valvuloplasty. *Phlebologie* 2014; 43: 210–212. DOI: <http://dx.doi.org/10.12687/phleb2207-4-2014>.
22. Labropoulos N, Tiongson J, Pryor L, et al. Definition of venous reflux in lower-extremity veins. *J Vasc Surg* 2003; 38: 793–798. DOI: 10.1016/s0741-5214(03)00424-5.
23. Hach W, Mumme A and Hach-Wunderle V. *Venenchirurgie*. Stuttgart, Germany: Schattauer GmbH, 2013.
24. Passman MA, McLafferty RB, Lentz MF, et al. Validation of venous clinical severity score (VCSS) with other venous severity assessment tools from the American Venous Forum, National Venous Screening Program. *J Vasc Surg* 2011; 54: 2S–9S. DOI: 10.1016/j.jvs.2011.05.117.
25. Allegra C, Antignani PL, Bergan JJ, et al. The “C” of CEAP: suggested definitions and refinements: an International Union of Phlebology conference of experts. *J Vasc Surg* 2003; 37: 129–131. DOI: 10.1067/mva.2003.47.
26. Stücker M, Moritz R, Altmeyer P, et al. New concept: different types of insufficiency of the saphenofemoral junction identified by duplex as a chance for a more differentiated therapy of the great saphenous vein. *Phlebology* 2013; 28: 268–274. DOI: 10.1177/0268355513476215.
27. Zolotukhin IA, Seliverstov EI, Zakharova EA, et al. Short-term results of isolated phlebectomy with preservation of incompetent great saphenous vein (ASVAL procedure) in primary varicose veins disease. *Phlebology* 2017; 32: 601–607. DOI: 10.1177/0268355516674415.
28. Pittaluga P, Chastanet S, Locret T, et al. The effect of isolated phlebectomy on reflux and diameter of the great saphenous vein: a prospective study. *Eur J Vasc Endovasc Surg* 2010; 40: 122–128. DOI: 10.1016/j.ejvs.2010.03.031.
29. Caggiati A, Rosi C, Heyn R, et al. Age-related variations of varicose veins anatomy. *J Vasc Surg* 2006; 44: 1291–1295. DOI: 10.1016/j.jvs.2006.07.040.
30. Perrin MR, Labropoulos N and Leon LR Jr. Presentation of the patient with recurrent varices after surgery (REVAS). *J Vasc Surg* 2006; 43: 327–334; discussion 334. DOI: 10.1016/j.jvs.2005.10.053.